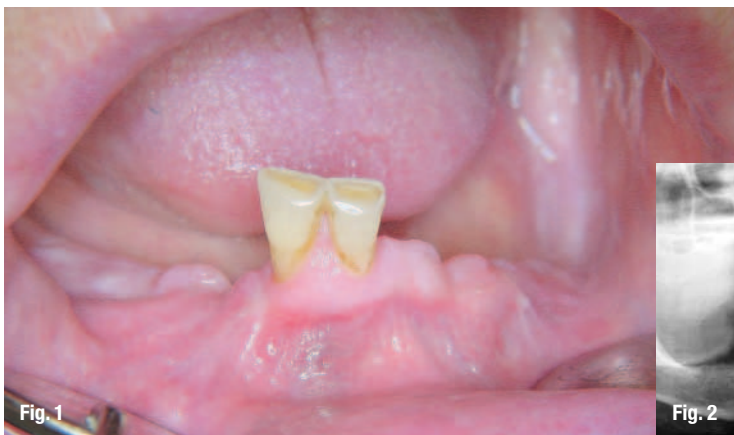

Immediate implant placement and immediate loading of the edentulous mandible

author_ Dr. Dirk W. Jaskolla, Uelzen, Germany

With increasing success rates in oral implantology, we are demanding to achieve a shorter healing time of implant prosthetic restorations for the benefit of the patients. The highest goal is to provide an immediate implant surgery with immediate loading at the same time.



patient came to our dental office with two remaining teeth in the lower right (teeth 41 and 42) (Fig. 1). The teeth did not offer sufficient support for a prosthetic restoration. The patient asked for a safe fixed

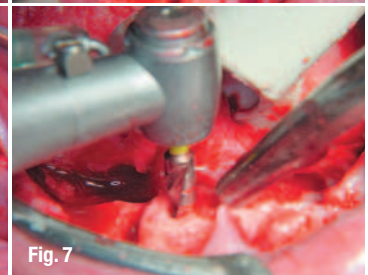
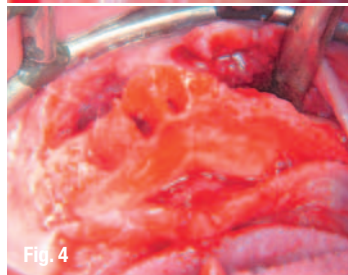
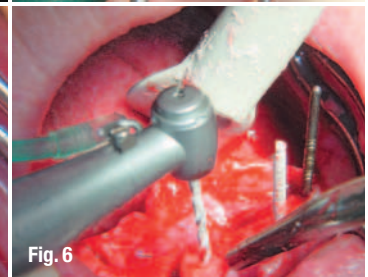
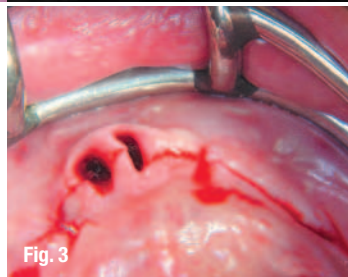
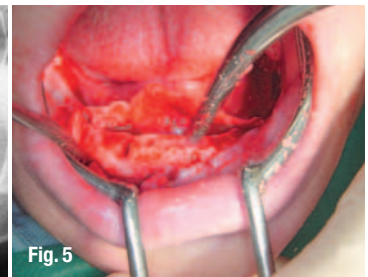
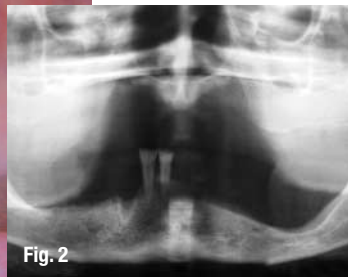

Fig. 1_ Pre-op situation.
Fig. 2_ Radiographic status pre-op.
Fig. 3_ Alveolar crest incision.
Fig. 4_ Situation prior to bone smoothing.
Fig. 5_ Creating a uniform crest level.
Fig. 6_ Preparation of the implant shaft with the twist drill.
Fig. 7_ Final drilling with the simultaneous drill.

_This prospect of reaching a high success prognosis has been described by Ledermann as early as 1979. The surgical technique has been confirmed as a safe therapy in the meantime. Ledermann described the restoration of an edentulous mandible with four implants in the interforaminal region, which he splinted primarily by a bar. The technique of this kind of restoration will be discussed in detail by example of the Pitt-Easy implant system of Oral-tronics. A 62-year old female

denture. In addition, there was a severe atrophy in the lower left, and the foramen mentale was very close to the alveolar crest so that any further atrophy had to be urgently avoided. In this case, we decided to remove the teeth and to insert in the same visit four Pitt-Easy implants which were provided with a bar and with the denture the same day. The bar was to be provided with distal attachments so that the area above the foramen mentale was no longer subject to any load pressure.

Preparation

Prior to the date of the surgery, a complete denture was prepared according to the conventional procedure. The two remaining teeth were spared at impression taking, the determination of the relation and the wax-up try-in. They were erased at the time of the final denture preparation. The prosthesis was then generously abraded in the area of tooth 34 to 44, so that there was sufficient space for impression-taking over the implants. The implant surgery was planned for the next morning, so that the dental technician had ample time to prepare the bar and including the bar clips into the denture until the evening.

Surgical procedure

After removal of the teeth, an alveolar crest incision was made to the distal (Fig. 3) that the foramina

mentale were safely exposed. The exposure of the foramina is very important with such surgery technique, because the distal implants should be placed as far to dorsal as possible. In this case we had to perform a bone smoothing due to the removal of teeth at the same time (Fig. 4 and 5). It is essential to create a sufficient alveolar crest width and a uniform bone level as far as possible, even if the Pitt-Easy system offers many components which are able to adjust any implant divergency and different insertion depths. The implants were inserted in region 34-32-42-44 (Fig. 6-9). As a next step, the permucosal extension of the confectioned Paracentric system was inserted for the required height (Fig. 10) in order to compensate severe differences in the insertion height (Fig. 10). In either case, the permucosal extensions should penetrate the gingiva as far as possible so that the conical Paracentric bar abutments could be placed above the gingiva onto the permucosal extensions and fixed (Fig. 12). This would facilitate the insertion of the bar later this day. After suturing the site, the acrylic caps prepared in the lab were placed onto the conical abutments (Fig. 13). These caps have to be manufactured precisely in order to guarantee a safe position, because in the lab the conical abutments have to be reposi-

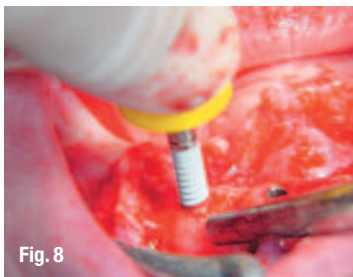


Fig. 8




Fig. 11

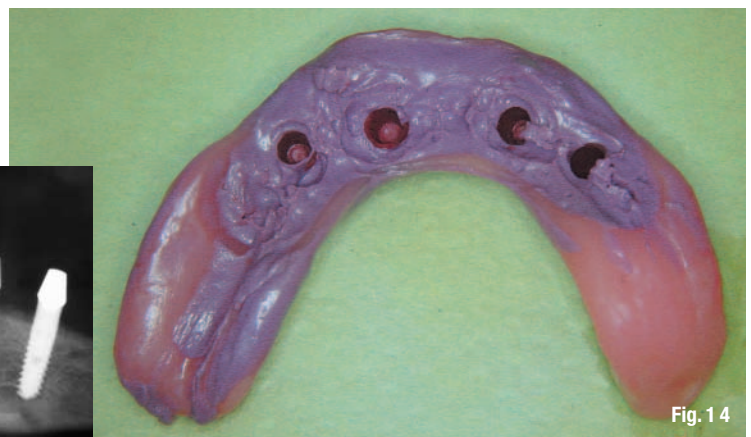

Fig. 14

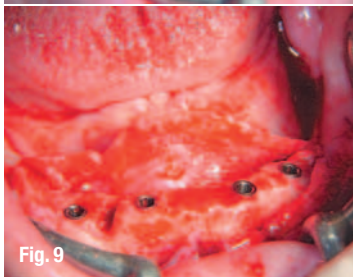


Fig. 9

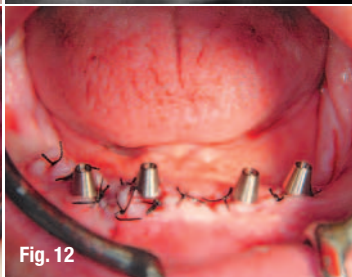

Fig. 12

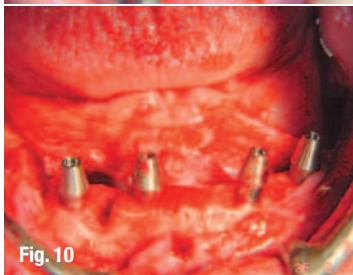


Fig. 10

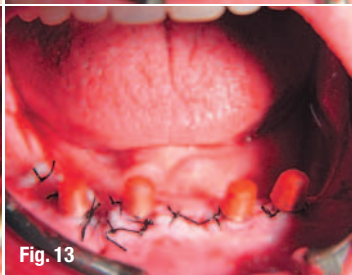

Fig. 13

tioned precisely into the impression. The following step is taking the impression with the generously abraded denture over the implants with the conical Paracentric bar abutments in place. In order to facilitate the insertion of the bar in the evening in a comfortable way for the patient and to avoid another anesthesia procedure, the bar connected abutments remain in the mouth of the patient. The technician receives the information which permucosal elements have been used. For the

- Fig. 8_** Manual insertion technique of a self-tapping Pitt-Easy implant.
- Fig. 9_** Four implants in situ.
- Fig. 10_** Conical Paracentric bar abutments in place.
- Fig. 11_** Post-operative X-ray control.
- Fig. 12_** Fixation of the bar abutments.
- Fig. 13_** Laboratory manufactured acrylic caps in place.
- Fig. 14_** Impression taking.

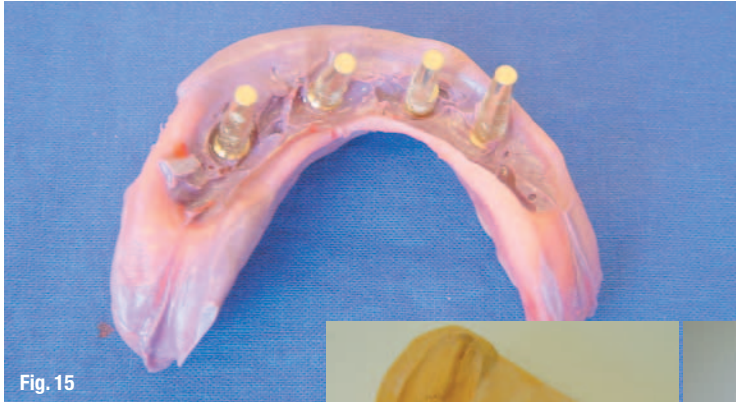

Fig. 15

Fig. 15_ Repositioning of the model analogs in the impression.

Fig. 16_ Model preparation.

Fig. 17_ Fixation of the bar segments in between the bar abutments.

Fig. 18_ Soldering the bar segments.

Fig. 19_ Positioning of the bar clips on the bar segments.

Fig. 20_ Polymerizing of the bar cips into the prosthesis.

Fig. 21_ The bar was screwed onto the paracentric permucosal extensions.

Fig. 22_ Insertion of the prosthesis.
Fig. 23_ Healthy condition of the gingiva, no irritation a few weeks post-op.



Fig. 16

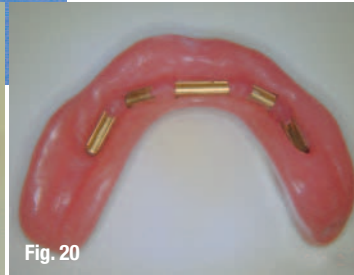


Fig. 20



Fig. 17

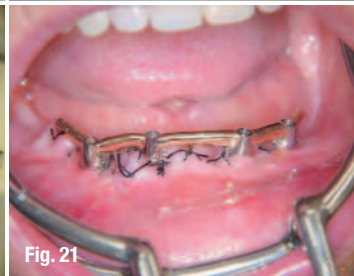

Fig. 21

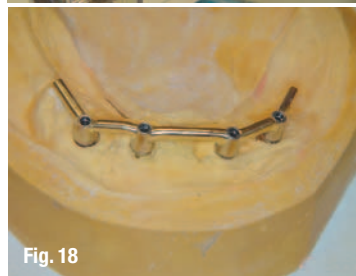

Fig. 18

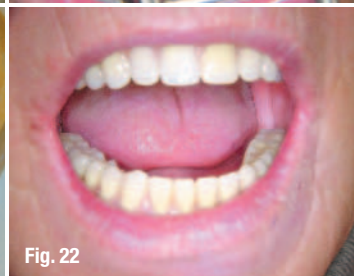

Fig. 22

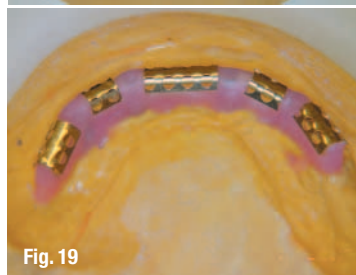


Fig. 19

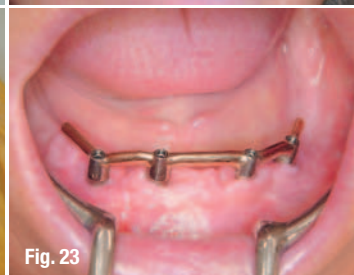

Fig. 23

the bar segments (Fig. 19) and polymerized into the denture (Fig. 20).

Insertion of the prosthesis

In the evening, the patient returns to have the bar abutments screwed off from the permucosal extensions. Since the separation is situated supra to paramarginal, this can be performed without anesthesia.

Only the final bar is screwed onto the permucosal extensions (Fig. 21) and the prosthesis tried in carefully (Fig. 22). As a rule, there is no significant gingival swelling so that the patient does not have any problems. An exact correction of the occlusion can take place only one to two weeks later. After a few weeks of good oral hygiene, the gingiva appears completely healthy (Fig. 23).

Conclusion

The procedure described above allows a final restoration for the patient within the shortest possible time. This represents the implant prosthetic concept which has been documented over the longest period of time and, therefore, has a predictable prognosis. In the step-by-step process we are using industrial prefabricated parts so that only a minimum of technical energy is required, resulting in the lowest possible expense for the patient. The three components of time, price and good prognosis has been combined in this technique for the benefit of the patient. _

preparation of the bar, he uses a second set of the conical bar abutments.

Paper in German language published in IMPLANTOLOGIE JOURNAL, DGZI, Edition 6/2005, September, Volume 9, Oemus Verlag, Germany

Laboratory procedure

The technician screws the corresponding permucosal extensions with the conical bar abutments onto the implant model analogs, in order to reposition them into the impression (Fig. 15) and to prepare a model (Fig. 16). Then the bar segments are fixed in between the bar abutments and soldered (Fig. 17 and 18). The bar clips are then placed onto

_contact	implants
<p>Dr. Dirk W. Jaskolla Bahnhofstr. 31a 29525 Uelzen Germany E-mail: Nevermann-Jaskolla@t-online.de</p>	